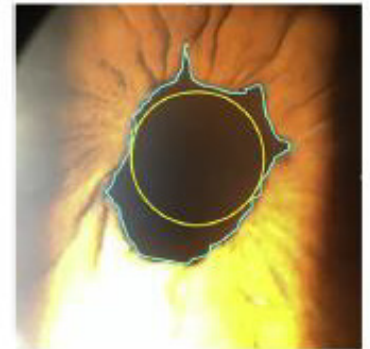
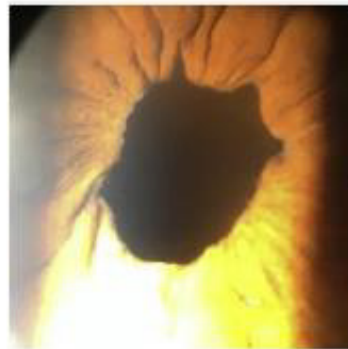
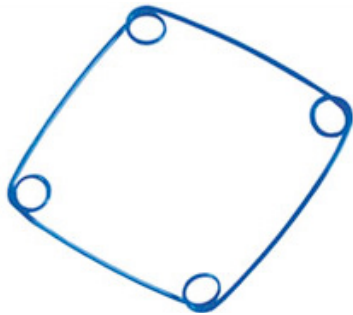


Comparison of 2 Pupil Expansion Devices for Small-Pupil Cataract Surgery

Doheny Eye Institute, California, USA

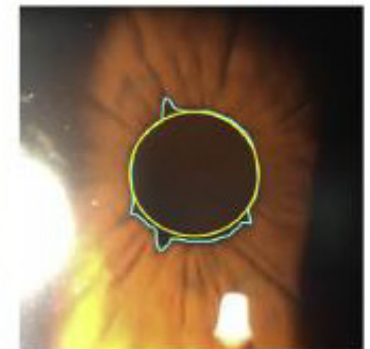
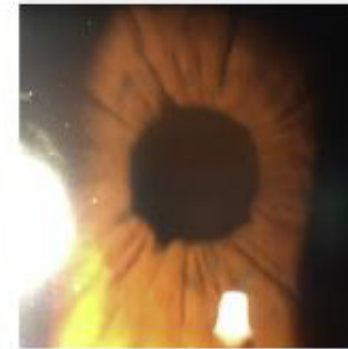
79-year-old white woman referred for bilateral nuclear cataract removal with no significant medical history

RIGHT EYE: Malyugin Ring (MST) used, no complications



3-month post-operative photo

LEFT EYE: (Surgery performed 1 month after the right eye), I-Ring (BVI) used, no intra-operative complications, 1st day post-operative follow-up showed minimal edema



2-month post-operative photo

The circular ring (I-Ring), constructed from a softer material, resulted in 11% distortion and the Malyugin ring, 49% distortion, suggesting that the circular ring caused less trauma to the iris.

Financial Disclosure: None of the authors has a financial or proprietary interest in any material or method mentioned.